



PATIENT

Juna Brown-Jeanbart

SPECIES

Feline

BREED

DSH

SEX

FS

AGE

10 y

WEIGHT

12.1 lb

INTERPRETED BY

Keith Blass, DVM, MS,
DACVIM (Cardiology)

IMAGING PERFORMED BY

Graham Sager-Gellerman, DVM

HOSPITAL NAME

Back Bay VC

REFERRING VET

Dr. Sager-Gellerman

INVOICE

DATE

2/13/26

PRESENTING CLINICAL SIGNS

Recheck HOCM. No current medications.

ECHOCARDIOGRAPHIC FINDINGS

2D, M-mode, and Doppler study. This exam is compared to the one performed 11/1/24.

Left atrial size is normal. There is mild hypertrophy of the left ventricular posterior wall and basilar-most portion of the interventricular septum. Left ventricular internal dimensions are normal. Left ventricular systolic function is normal. There is systolic anterior motion of the mitral valve leaflets creating mild dynamic obstruction to flow in the left ventricular outflow tract, with mild secondary mitral regurgitation. The aorta and aortic valve appear normal, though mild aortic insufficiency is present. Right atrial and right ventricular dimensions are normal. The tricuspid valve appears normal, though trace tricuspid regurgitation is present. The pulmonary artery and pulmonic valve are normal. No pericardial effusion or cardiac masses are seen.

LA/Ao – 1.47 (prev. 1.39)
IVSd – 6.2 mm (prev. 6.2 mm)
LVPWd – 6.1 mm (prev. 6.1 mm)
LVIDd – 11.8 mm (prev. 11.9 mm)
LVIDs – 5.6 mm (prev. 5.9 mm)
FS – 52.5% (prev. 50.4%)
LVOT – 2.00 m/s (prev. 3.27 m/s)
RVOT – 0.93 m/s (prev. 1.01 m/s)

ASSESSMENT/RECOMMENDATIONS

Degenerative mitral and tricuspid valve disease

This examination demonstrates no progression of Juna's cardiac disease over the past 15 months. As such, her risk for the development of congestive heart failure and/or thromboembolic disease still appears to be relatively low.

No therapy is recommended based on this exam.

A recheck echocardiogram is recommended in 9 months. Thoracic radiographs are recommended if Juna experiences labored breathing.



PATIENT

Juna Brown-Jeanbart

SPECIES

Feline

BREED

DSH

SEX

FS

AGE

10 y

WEIGHT

12.1 lb

INTERPRETED BY

Keith Blass, DVM, MS,
DACVIM (Cardiology)

IMAGING PERFORMED BY

Graham Sager-Gellerman, DVM

HOSPITAL NAME

Back Bay VC

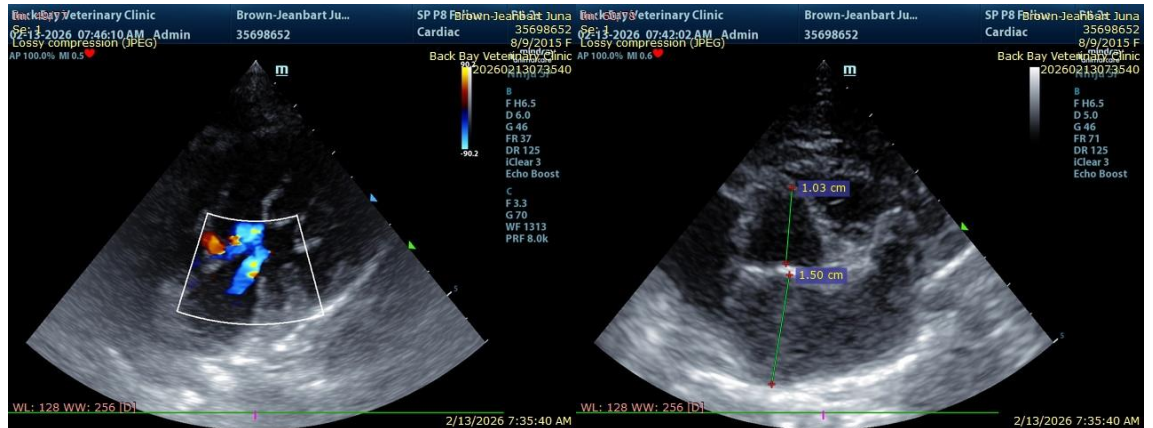
REFERRING VET

Dr. Sager-Gellerman

INVOICE

DATE

2/13/26



The information and recommendations provided are based on the images presented by the referring veterinarian/sonographer. No evaluation can be communicated regarding pathology that was not visible in the image/video clips provided.

Thank you for this referral. If the clinical or image interpretation does not parallel your findings or if I can be of any further assistance please contact me.

Keith Blass, DVM, MS, DACVIM (Cardiology) info@SonoPath.com